

Right Ventricular Dilatation on Bedside Echocardiography Performed by Emergency Physicians Aids in the Diagnosis of Pulmonary Embolism

Scott Dresden, MD; Patricia Mitchell, RN; Layla Rahimi, BA; Megan Leo, MD, RDMS; Julia Rubin-Smith, MPH; Salma Bibi, MPH; Laura White, PhD; Breanne Langlois, MPH; Alison Sullivan, MD; Kristin Carmody, MD, RDMS

Study objective: The objective of this study was to determine the diagnostic performance of right ventricular dilatation identified by emergency physicians on bedside echocardiography in patients with a suspected or confirmed pulmonary embolism. The secondary objective included an exploratory analysis of the predictive value of a subgroup of findings associated with advanced right ventricular dysfunction (right ventricular hypokinesis, paradoxical septal motion, McConnell's sign).

Methods: This was a prospective observational study using a convenience sample of patients with suspected (moderate to high pretest probability) or confirmed pulmonary embolism. Participants had bedside echocardiography evaluating for right ventricular dilatation (defined as right ventricular to left ventricular ratio greater than 1:1) and right ventricular dysfunction (right ventricular hypokinesis, paradoxical septal motion, or McConnell's sign). The patient's medical records were reviewed for the final reading on all imaging, disposition, hospital length of stay, 30-day in-hospital mortality, and discharge diagnosis.

Results: Thirty of 146 patients had a pulmonary embolism. Right ventricular dilatation on echocardiography had a sensitivity of 50% (95% confidence interval [CI] 32% to 68%), a specificity of 98% (95% CI 95% to 100%), a positive predictive value of 88% (95% CI 66% to 100%), and a negative predictive value of 88% (95% CI 83% to 94%). Positive and negative likelihood ratios were determined to be 29 (95% CI 6.1% to 64%) and 0.51 (95% CI 0.4% to 0.7%), respectively. Ten of 11 patients with right ventricular hypokinesis had a pulmonary embolism. All 6 patients with McConnell's sign and all 8 patients with paradoxical septal motion had a diagnosis of pulmonary embolism. There was a 96% observed agreement between coinvestigators and principal investigator interpretation of images obtained and recorded.

Conclusion: Right ventricular dilatation and right ventricular dysfunction identified on emergency physician performed echocardiography were found to be highly specific for pulmonary embolism but had poor sensitivity. Bedside echocardiography is a useful tool that can be incorporated into the algorithm of patients with a moderate to high pretest probability of pulmonary embolism. [Ann Emerg Med. 2014;63:16-24.]

Please see page 17 for the Editor's Capsule Summary of this article.

A **feedback** survey is available with each research article published on the Web at www.annemergmed.com.

A **podcast** for this article is available at www.annemergmed.com.

0196-0644/\$-see front matter

Copyright © 2013 by the American College of Emergency Physicians.

<http://dx.doi.org/10.1016/j.annemergmed.2013.08.016>

INTRODUCTION

Background

Pulmonary embolism is a common and highly lethal entity that is often misdiagnosed.¹ Despite an increased awareness of pulmonary embolism and improved diagnostic testing, there are still a significant number of fatal pulmonary embolisms not diagnosed until autopsy.¹⁻⁴ An estimated 1.35 million Americans have a pulmonary embolism every year.⁵ Short-term mortality estimates vary widely, from 2.5% to as high as 33%.⁶⁻⁸ Twenty-five thousand pulmonary embolism-related deaths are recorded annually in the United States,⁹ but this is likely an underestimation of the true mortality because of the ones not discovered until autopsy.

Pulmonary embolism causes morbidity and mortality through right ventricular outflow obstruction, which may lead to increased pulmonary artery pressure, right ventricular failure, left ventricle failure, and circulatory collapse. Right ventricular dysfunction has been found on echocardiography in 27% to 40% of normotensive patients with a pulmonary embolism and can predict hemodynamic instability and circulatory collapse.^{8,10,11} Evidence of right ventricular dysfunction on echocardiography includes dilatation of the right ventricle (Figure 1), right ventricular hypokinesis, paradoxical septal motion (flattening or bowing of the interventricular septum toward the left ventricle), McConnell's sign (right ventricular free wall hypokinesis with apical sparing), and tricuspid regurgitation.¹²⁻¹⁶

Editor's Capsule Summary

What is already known on this topic

Right ventricular dysfunction on echocardiography is associated with a worse prognosis in pulmonary embolism. Prompt treatment of pulmonary embolism appears to be associated with better outcomes.

What question this study addressed

Can emergency department bedside echocardiography in patients with suspected pulmonary embolism reliably identify those who have right ventricular dysfunction, potentially leading to earlier diagnosis and treatment?

What this study adds to our knowledge

This observational study of a convenience sample of 146 patients with moderate to high risk or confirmed pulmonary embolism found that right ventricular dysfunction was highly specific for pulmonary embolism.

How this is relevant to clinical practice

Bedside echocardiography may be a useful addition to diagnostic protocols for suspected pulmonary embolism, but how much it adds to other clinical findings remains to be determined.

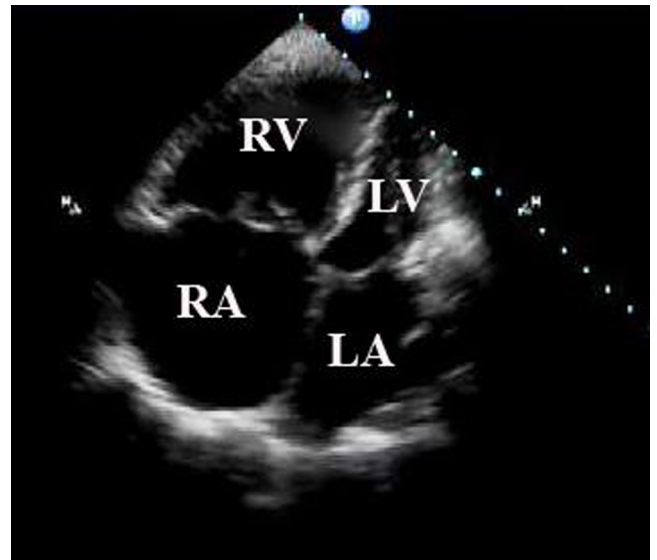

Figure 1. Right ventricular dilatation (right ventricle:left ventricle ratio >1:1) in this apical 4-chamber image of a patient with an acute pulmonary embolism. RV, right ventricle; LV, left ventricle; RA, right atrium; LA, left atrium.

disposition could be expedited, resulting in a possible reduction in morbidity and mortality.

Goals of This Investigation

The primary objective of this study was to determine the diagnostic performance of right ventricular dilatation as identified by emergency physicians on bedside echocardiography in patients with suspected or confirmed diagnosis of pulmonary embolism. The secondary objective included an exploratory analysis of the predictive value of a subgroup of sonographic findings associated with advanced right ventricular dysfunction on bedside echocardiography, including signs of right ventricular hypokinesis, paradoxical septal motion, and McConnell's sign.

MATERIALS AND METHODS

Study Design and Setting

We performed a prospective observational study, using a convenience sample of ED patients with suspected or confirmed pulmonary embolism, from June 2009 to August 2011. The study was performed in the ED at Boston Medical Center, a large urban academic medical center with greater than 130,000 annual visits. The ED is staffed by board-certified emergency physicians and emergency medicine residents. The institutional review board at the Boston University School of Medicine approved this study.

Four trained physician-investigators took part in the study and performed all of the bedside ultrasounds. The principal investigator of the study was the ultrasound director at Boston Medical Center, who had formal emergency ultrasound

Importance

Two thirds of patients who die from a pulmonary embolism do so within the first hour of presentation, and 75% of deaths occur during the initial hospitalization.^{8,17} Prompt treatment has been associated with lower mortality rates.^{6,18,19} Diagnosis of pulmonary embolism can be delayed by a number of problems, including difficulty obtaining intravenous access, renal impairment resulting in the inability to administer intravenous contrast, wait times for imaging, and the inability to obtain some imaging at certain times of day. These delays can impede the initiation of treatment and may lead to increased mortality.^{6,18}

The utility of point-of-care ultrasound in the emergency department (ED) is well established. It includes the use of bedside echocardiography by emergency physicians to diagnose pericardial effusion, right ventricular strain, cardiac function, and volume status.²⁰ The presence of right ventricular dilatation on echocardiography in patients with a pulmonary embolism has been shown to be associated with permanent right ventricular dysfunction, right ventricular failure, recurrent pulmonary embolism, and death.^{11,21,22} If a dilated right ventricle is identified on bedside echocardiography in patients with a suspicion of pulmonary embolism, decisions about treatment and

fellowship training, as well as current registered diagnostic medical sonographer and registered diagnostic cardiac sonographer certifications. The other 3 physician-investigators were required to complete minimum training requirements before participating in the study, which included a standard 1-month ultrasound rotation during residency, satisfying the 2008 American College of Emergency Physicians recommendations.²³ Each of the 3 physicians had completed a minimum of 25 cardiac ultrasounds before their participation in the study. In addition, the 3 investigators were required to participate in 5 additional hands-on (total of 10 hours) and image review sessions (total of 10 hours) with the principal investigator to ensure adequacy of their cardiac image acquisition and interpretations. Two of the nonprincipal investigators were residents and 1 was an ultrasound fellow throughout the study enrollment period.

Selection of Participants

Participants were identified for inclusion by attending physicians and emergency medicine residents working in the ED. If a patient was deemed eligible, a trained ED research assistant or one of the physician-investigators was contacted for enrollment and consent. In addition, the ED research assistants monitored the hospital electronic charting system from 8 AM to 11 PM Monday through Friday, screening for eligible patients. Patients were approached for enrollment if they met inclusion criteria: older than 21 years, a moderate to high pretest probability of pulmonary embolism (Wells score ≥ 2 , calculated by the treating physician), with an intent to obtain definitive imaging for pulmonary embolism (computed tomography [CT] pulmonary angiogram or ventilation-perfusion scan), as determined by examining the electronic medical record or a documented pulmonary embolism on imaging already performed before arrival to the ED. Non-English speakers and prisoners were excluded. Written informed consent was obtained from stable patients, whereas those who were unstable or unable to provide written informed consent were enrolled with a waiver of informed consent as approved by the Boston University School of Medicine institutional review board.

Interventions and Data Collection and Processing

After consent was obtained or waived, one of the trained physician-investigators performed a bedside echocardiography in the ED and completed a data collection sheet. Information collected included patients' demographics, vital signs, presenting symptoms, Wells criteria, echocardiography results, and results of definitive imaging. The Wells score was calculated and recorded for all patients with suspected pulmonary embolism before definitive imaging was reported and documented. Patients with a diagnosed pulmonary embolism prior to arrival in the ED were enrolled regardless of the Wells score. Physicians who performed the bedside echocardiography on any patient were blinded to the results of any confirmatory studies (CT pulmonary

angiogram or ventilation-perfusion scan) for those who had imaging in the ED. Definitive imaging results were not recorded on the data sheet until after the echocardiography was performed and documented.

The echocardiography views obtained and recorded were parasternal long axis, parasternal short axis, and apical 4-chamber (A4C) views. There were several measurements obtained and documented on the data collection sheet. The primary measurement included a qualitative assessment of right ventricular size compared with left ventricular size on 2-dimensional echocardiography. On an apical A4C view, the normal right ventricular:left ventricular ratio is approximately 0.6:1.0. An increase in the right ventricular:left ventricular ratio was qualitatively measured as both an enlarged right ventricular length and diameter and a distension of the right ventricular apex adjacent to the left ventricular apex. The right ventricular and left ventricular sizes were assessed qualitatively on A4C images by the sonographer at end diastole, and the right ventricular:left ventricular ratio was defined as abnormal if it exceeded 1:1.

Other measurements obtained and documented included a quantitative measurement of right ventricular and left ventricular diameter measured across the tips of the tricuspid and mitral valves in an A4C view (measured in centimeters) and a qualitative analysis of right ventricular function (normal or hypokinetic). In addition, the presence of paradoxical septal motion and McConnell's sign was also recorded and documented (present or absent). The results of the echocardiography were documented on the data collection sheet and conveyed to the attending physician caring for the patient in the ED, as required by the institutional review board. The bedside echocardiography interpretations were documented in the medical record only at the discretion of the physician taking care of the patient in the ED. All cardiac views were obtained with a Philips (Amsterdam, the Netherlands) HD11 XE machine with a phased-array probe. Images were digitally recorded and stored for review. An expert cardiac sonographer (the study principal investigator), who was blinded to all clinical information and outcome data, independently reviewed all recorded images. The review ensured adequate image acquisition and interpretation to determine the percentage of observed agreement.

The patient's medical records were later reviewed by trained ED research assistants, and the final reading on all definitive imaging studies was documented. The final reading was the formal dictated report by an attending radiologist in the medical record. The imaging reports were coded as no evidence of pulmonary embolism or reported as a positive pulmonary embolism result. Pulmonary embolism was categorized by location (saddle, mainstem, lobar, segmental, or subsegmental embolus). The presence of a saddle, mainstem, or lobar embolus was considered to be more proximal, with a larger clot burden, whereas segmental and subsegmental emboli were considered more distal, with a smaller clot burden. The disposition (home, floor, or ICU), hospital length of stay, 30-day in-hospital mortality, and hospital discharge diagnosis were abstracted.

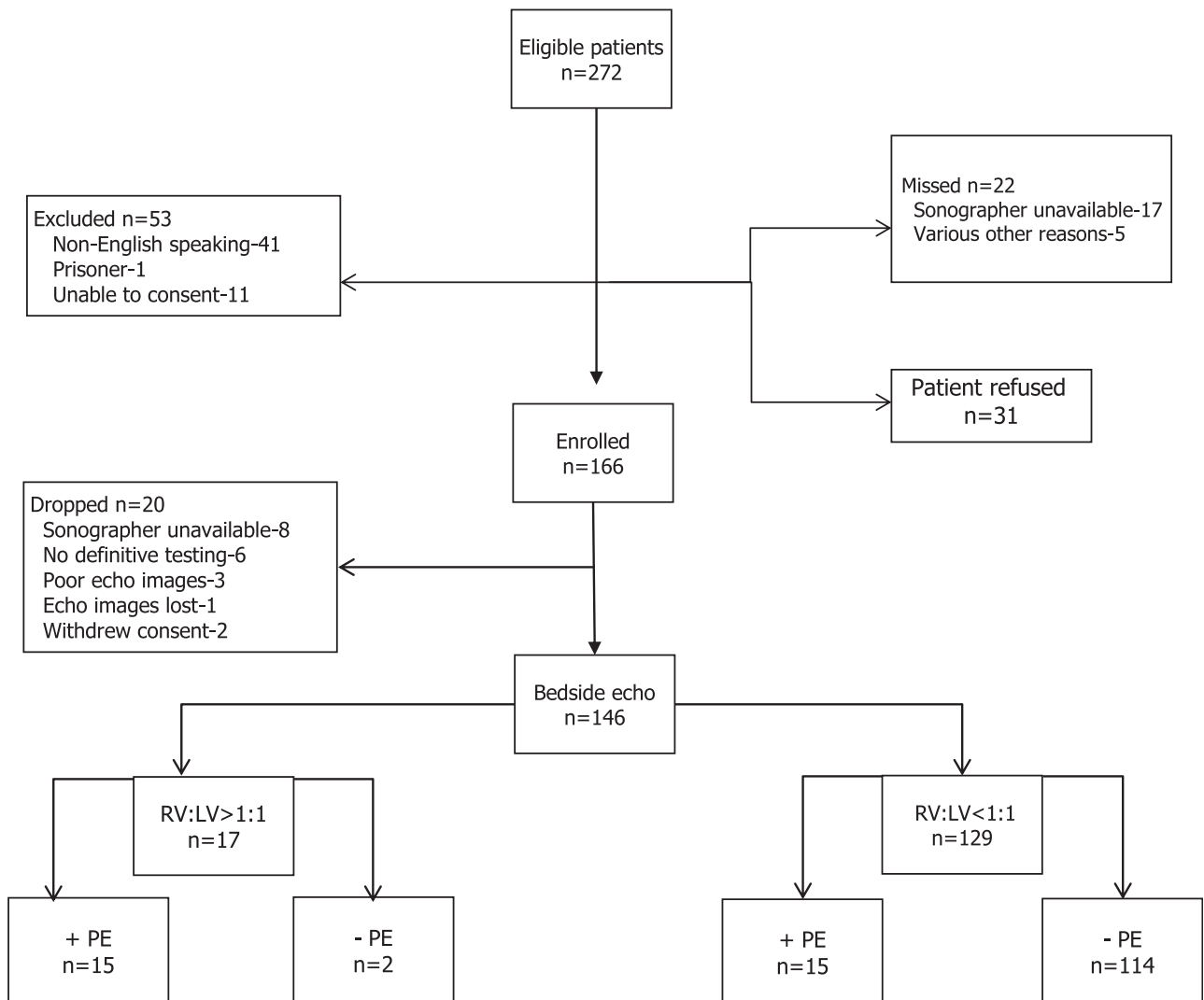


Figure 2. Flow of patients through the study. *Echo*, echocardiography; *RV*, right ventricle; *LV*, left ventricle; *PE*, pulmonary embolism.

The principal investigator reviewed all medical records a second time to ensure adequate interpretations of all results and dispositions. If there was a discrepancy between the chart review of a research assistant and the principal investigator, the principal investigator's interpretation was used as the medical expert.

Outcome Measures

The primary outcome measures for this study were diagnostic characteristics (sensitivity, specificity, positive predictive value, negative predictive value, and positive and negative likelihood ratios) of right ventricular dilatation on bedside echocardiography in patients with a pulmonary embolism. Right ventricular dilatation was defined as a right ventricular:left ventricular ratio of 1:1 or greater. The secondary exploratory outcome measures were the presence of advanced signs of right ventricular dysfunction on echocardiography (right ventricular hypokinesis [qualitatively assessed as normal or hypokinetic], paradoxical septal motion, and McConnell's sign).

Primary Data Analysis

We used SAS (version 9.2; SAS Institute, Inc., Cary, NC) to analyze the data. We calculated descriptive statistics to analyze the study population. Sensitivity, specificity, positive predictive value, negative predictive value, and positive and negative likelihood ratios were calculated with 95% confidence intervals (CIs). The blinded review by the principal investigator of all recorded images was reported as the percentage of observed agreement because of the measurements' being recorded on a continuous scale. We also described the relationship between the most proximal location of pulmonary embolism and the presence or absence of right ventricular dilatation on bedside echocardiography.

The sample size of approximately 150 patients was calculated according to previous estimates of sensitivity and specificity of right ventricular dilatation on echocardiography in the diagnosis of pulmonary embolism.²⁴ One study by Bova et al²⁴ showed that right ventricular dilatation on echocardiography has poor

sensitivity (approximately 31%) but high specificity (approximately 94%) in the diagnosis of pulmonary embolism. In this study, right ventricular dilatation was assessed by qualitative visual comparison in an A4C view. The right ventricle was considered dilated if its size was equal to or greater than the size of the left ventricle. Other studies have reported higher sensitivities in using echocardiography to diagnose pulmonary embolism but enrolled patients with a known pulmonary embolism, which could have introduced bias.^{25,26} One additional study with higher reported sensitivity used the combination of at least 2 criteria on echocardiography to diagnose a pulmonary embolism (right ventricular dilatation, tricuspid regurgitation, or right ventricular hypokinesis).²⁷

Although an echocardiography result with signs of right ventricular dilatation helps in identifying patients with a pulmonary embolism, one with a normal right ventricular:left ventricular ratio should not rule out the diagnosis. Therefore, our sample size was calculated with a confidence level of 95% with the intention of maintaining a narrow CI (0.10) surrounding the specificity.

RESULTS

Between June 2009 and August 2011, 272 patients with a moderate to high pretest probability of pulmonary embolism were identified during study hours and either had imaging ordered in the ED or were diagnosed with a pulmonary embolism prior to arrival (Figure 2). Fifty-three patients were excluded from the study (41 were non-English speaking, 1 was a prisoner, and 11 were unable to be approached for informed consent for reasons that did not meet waiver of consent criteria). Of the 11 patients who did not meet waiver of consent criteria, 4 were intoxicated and uncooperative and 7 had the attending physician taking care of the patient refuse the study because of interference with patient care. Twenty-two patients were missed (17 were identified during screening hours, but a sonographer was not available; 5 were missed because they left the ED before the research assistant was able to ask for consent). Thirty-one patients were approached and declined to participate. One hundred sixty-six patients were enrolled in the study. Of these, 20 patients were dropped (8 were dropped because the sonographer was unable to perform the echocardiography before the patient left the ED, 6 had their formal imaging study cancelled due to the treating physician’s decision or to the patient’s refusing imaging, 3 had poor-quality images on the echocardiography, 1 echocardiograph was not saved for review, and 2 withdrew consent). Four participants were enrolled with a waiver of informed consent (3 unstable, 1 with dementia).

A total of 146 participants were included in the final analysis. Baseline demographics of the 146 participants, Wells score, and the presence or absence of right ventricular dilatation on bedside echocardiography are presented in Table 1. Of the 146 patients included in the analysis, 126 (86%) were classified as having a moderate pretest probability for pulmonary embolism and 20 (14%) were classified as having a high one by Wells criteria. The prevalence of pulmonary embolism in this sample population was

Table 1. Patient demographics, medical history, social history, and pretest Wells score.

Characteristic	Overall (n=146)	RV:LV <1:1 (n=129)	RV:LV >1:1 (n=17)
Mean age (SD), y	49 (16)	48 (15)	58 (17)
Sex, No. (%)			
Women	92 (63)	85 (66)	7 (41)
Ethnicity, No. (%)			
Black	84 (58)	73 (57)	11 (65)
White	44 (30)	38 (29)	6 (35)
Hispanic	14 (10)	14 (11)	0
Asian	1 (0.7)	1 (0.8)	0
Other	3 (2)	3 (2)	0
Medical/social history, No. (%)			
Previous PE/DVT	21 (14)	17 (13)	4 (24)
Clotting disorder	4 (3)	2 (2)	2 (12)
Heart disease	20 (14)	18 (14)	2 (12)
Hypertension	41 (28)	33 (26)	8 (47)
Diabetes	24 (16)	23 (18)	1 (6)
COPD	15 (10)	11 (9)	4 (24)
Active cancer	9 (6)	6 (5)	3 (18)
Tobacco use	24 (16)	24 (19)	0
Pregnant	1 (0.7)	1 (0.8)	0
Wells criteria, No. (%)			
High probability (>6)	20 (14)	13 (10)	7 (41)
Moderate probability (2–6)	126 (86)	116 (90)	10 (59)

RV, right ventricle; LV, left ventricle; PE, pulmonary embolism; DVT, deep venous thrombosis; COPD, chronic obstructive pulmonary disease.

21% (30/146) (Table 2). Pulmonary embolism was identified in 26 patients by CT pulmonary angiogram, 2 by CT thorax with intravenous contrast, 1 by positron emission tomography scan, and 1 by digital subtraction angiography. No patients in the sample had a ventilation-perfusion scan performed.

Of these 146 patients, 129 had a normal right ventricular:left ventricular ratio on echocardiography and 17 had an increased right ventricular:left ventricular ratio on echocardiography. There was a 96% observed agreement on all images reviewed between the principal investigator and the other 3 physician-investigators. Of the 30 patients with pulmonary embolism, right ventricular dilatation was identified in 15 patients, whereas it was absent in 114 of 116 patients without a pulmonary embolism. There were 2 patients with right ventricular dilatation who did not have a confirmed pulmonary embolism. Both of these patients had chronic obstructive pulmonary disease, which can exhibit signs of chronic right ventricular dysfunction on echocardiography (Table 2). Identification of right ventricular dilatation on bedside echocardiography for the diagnosis of pulmonary embolism had a sensitivity of 50% (95% CI 32% to 68%), a specificity of 98% (95% CI 95% to 100%), a positive predictive value of 88% (95% CI 66% to 100%), and a negative predictive value of 88% (95% CI 83% to 94%). Positive likelihood ratio and negative likelihood ratio were determined to be 29 (95% CI 6.1% to 64%) and 0.51 (95% CI 0.4% to 0.7%), respectively.

There were 5 cases in which the patient had a positive pulmonary embolism diagnosed prior to enrollment in the study (2 had one diagnosed on an outpatient CT thorax conducted on

Table 2. Bedside echocardiography and imaging results in study patients.

Echocardiography Findings	+PE	-PE	Total
RV:LV >1:1	15	2	17
RV:LV <1:1	15	114	129
Total	30	116	146
RV hypokinesis	10	1	11
McConnell's sign	6	0	6
Paradoxical septal motion	8	0	8

the same day; 1, on a positron emission tomography scan conducted as an outpatient; 1, on a CT pulmonary angiogram on an ED visit the day before that was originally read as negative and who was called back for a reread of a positive result; and 1 was transferred from an outside institution for a pulmonary embolism diagnosed on a CT pulmonary angiogram. Of these 5 patients, 1 had signs of right ventricular dilatation and 4 had a normal right ventricular:left ventricular ratio on the bedside echocardiography. An expert cardiac sonographer, blinded to all clinical information, independently reviewed the recorded echocardiography images on all of these patients, and there was 100% observed agreement in identification of right ventricular dilatation on echocardiography. These 5 cases were mixed in with all other recorded images of enrolled patients, and therefore the principal investigator was unaware that these patients had been diagnosed with a pulmonary embolism prior to arrival to the ED.

Additional echocardiographic findings, found in a subset of patients in this study, were also observed and recorded (Table 2). Eleven patients had signs of right ventricular hypokinesis on echocardiography, of whom 10 had a confirmed diagnosis of pulmonary embolism (sensitivity 33%, 95% CI 16% to 50%; specificity 99%, 95% CI 97% to 100%). All 6 patients with McConnell's sign had a diagnosis of pulmonary embolism (sensitivity 20%, 95% CI 5.7% to 34%; specificity 100%, 95% CI 96.74% to 100%), and all 8 patients with paradoxical septal motion had a diagnosis of pulmonary embolism (sensitivity 27%, 95% CI 11% to 43%; specificity 100%, 95% CI 96.65% to 100%). There was 100% observed agreement between the principal investigator's blinded review and the sonographer's interpretation of these advanced right ventricular dysfunction findings.

Of the 30 patients with a diagnosed pulmonary embolism, only 3 were treated in the ED before definitive imaging. Two patients were hemodynamically unstable and both had signs of right ventricular dilatation and dysfunction on the bedside echocardiography and received thrombolytics to treat a probable pulmonary embolism. One patient had a history of pulmonary embolism and had stopped receiving his home warfarin several days before. The patient received anticoagulation before imaging because of the pretest probability and clinical suspicion of the physician. The remaining 27 patients did not receive treatment before the imaging study even when signs of right ventricular dilatation or dysfunction were visualized on bedside echocardiography and relayed to the physician taking care of the patient.

Table 3. Most proximal clot location and presence or absence of right ventricular dilatation.

Most Proximal Clot Location	RV:LV >1:1	RV:LV <1:1	Total
Saddle	4	0	4
Mainstem	3	1	4
Lobar	6	3	9
Segmental	2	10	12
Subsegmental	0	0	0
Unknown	0	1	1
Totals	15	15	30

The location of pulmonary embolism in 29 patients was determined by examining the final attending radiology reading on all imaging studies. One patient had an unknown clot location because the CT pulmonary angiogram was conducted as an outpatient at another hospital before the patient's arrival to the ED. The images and final attending reading were unavailable because of the inability to obtain the report or images while the patient was still in the ED and because the patient was subsequently lost to follow-up. The relationship between the most proximal location of pulmonary embolism in the 29 patients and the presence or absence of right ventricular dilatation was explored (Table 3). Of the 15 patients with confirmed pulmonary embolism and right ventricular dilatation on bedside echocardiography, most had more proximal clots (4 had saddle emboli, 3 had mainstem emboli, 6 had lobar emboli, and only 2 had segmental emboli). Of the 15 patients with confirmed pulmonary embolism and a normal right ventricular:left ventricular ratio on bedside echocardiography, most had more distal clots (10 had segmental emboli, 1 had a mainstem embolus, 3 had lobar emboli, and 1 had an unknown clot location).

Eight of the 30 patients with a diagnosis of a pulmonary embolism were admitted to the ICU (Table 4). All 8 of these patients had multiple pulmonary emboli diagnosed on their imaging studies, with the most proximal clot location recorded. Four patients had saddle emboli, 1 patient had a mainstem embolus, and 3 patients had lobar emboli as their most proximal sites. All 8 patients admitted to the ICU had signs of right ventricular dilatation on the bedside echocardiography, and all had an acute pulmonary embolism(s) diagnosed by imaging (7 had a CT pulmonary angiogram; 1 had digital subtraction angiography from the ICU because of instability in the ED and definitive imaging could not be obtained). Additional echocardiographic findings included right ventricular hypokinesis in 7 patients, McConnell's sign in 5 patients, and paradoxical septal motion in 7 patients. Two of the 8 ICU patients died during admission; both patients had right ventricular dilatation, right ventricular hypokinesis, McConnell's sign, and paradoxical septal motion on bedside echocardiography.

LIMITATIONS

This was a single-site study performed at an academic ED with emergency medicine residents and an active ultrasound

Table 4. ICU patients with a diagnosed pulmonary embolism (n=8).

Patient	Most Proximal PE	Wells Score	RV:LV >1:1	RV Hypo	MCS	PSM	Dispo
	1	Lobar	9	+	+	+	
2	Saddle	7.5	+	+	+	+	Discharge
3	Lobar	3	+	-	-	-	Discharge
4	Mainstem	9	+	+	+	+	Discharge
5	Lobar	4.5	+	+	-	+	Discharge
6	Saddle	4.5	+	+	+	+	Discharge
7	Saddle	4.5	+	+	-	+	Discharge
8	Saddle	7	+	+	+	+	Deceased

ICU, intensive care unit; PE, pulmonary embolism; RV, right ventricle; LV, left ventricle; RV Hypo, right ventricular hypokinesis; MCS, McConnell's sign; PSM, paradoxical septal motion; Dispo, disposition.

section. The physician-investigators all completed special training requirements in cardiac sonography to be part of this study. These results may not be easily reproduced by other emergency physicians who do not have ultrasound requirements in residency, are further removed from their ultrasound training, or who did not specifically receive training in cardiac sonography. The experience of the operators may lead to difficulty generalizing these results to other sites with fewer resources and training.

This study was a convenience sample because of the limitations in the enrolling physicians' availabilities. One of the 4 physician-investigators needed to be present to perform the echocardiography in the ED. It is possible that convenience sampling or sonographer availability introduced selection biases in the population studied.

The use of 2 strategies for the inclusion criteria (patients with moderate to high Wells scores and an intent to obtain definitive imaging in addition to patients with an already diagnosed pulmonary embolism on imaging) could be considered a limitation in this study. The lack of blinding to the results of the diagnostic test in these 5 cases could also have affected the sonographer's interpretation of right ventricular dilatation and dysfunction. Despite the potential for bias in these 5 cases, the images were blindly reviewed by the principal investigator and had an observed agreement of 100% and an overall agreement of 96%.

Our study was not powered for the secondary outcomes of advanced right ventricular dysfunction on echocardiography, including right ventricular hypokinesis, paradoxical septal motion, and McConnell's sign. These additional characteristics were considered exploratory for the purposes of our study. A larger study would need to be conducted to confirm the emergency physicians' capabilities at reliably identifying these findings on echocardiography and their proper use in clinical care.

DISCUSSION

In this study, we found that right ventricular dilatation on bedside echocardiography was highly specific for pulmonary embolism (98%) but had poor sensitivity (50%). Our study

showed very high specificity compared with that found in previous literature. It is likely that the younger age (mean of 49 years) of our patient population enrolled eliminated many patients with chronic obstructive pulmonary disease who can have signs of chronic right ventricular dysfunction on echocardiography. The results of our study suggest that finding right ventricular dilatation on bedside echocardiography may help emergency physicians rule in pulmonary embolism more rapidly by raising a provider's index of suspicion before definitive testing. In addition, the high positive likelihood ratio (29) in our study shows that the presence of right ventricular dilatation on bedside echocardiography increased the pretest probability of a diagnosis of pulmonary embolism before definitive imaging was performed. This study supports the concept that patients with a moderate to high pretest probability for pulmonary embolism and a bedside echocardiography result showing right ventricular dilatation should be considered for anticoagulation before definitive testing. This concept is supported by current practice guidelines, which suggest empiric anticoagulation in patients at high risk for pulmonary embolism.²⁸ However, a normal right ventricular:left ventricular ratio on echocardiography does not eliminate the diagnosis and definitive imaging is required to rule out pulmonary embolism.

In addition, more advanced findings such as right ventricular hypokinesis, paradoxical septal motion, and McConnell's sign may also be helpful in making the diagnosis. Ten of 11 patients with right ventricular hypokinesis had a diagnosed pulmonary embolism and all patients with McConnell's sign or paradoxical septal motion had a diagnosed pulmonary embolism. Our study found that these advanced findings have high specificity for the diagnosis of pulmonary embolism but, similar to right ventricular dilatation, have low sensitivity. Most of the patients with these advanced echocardiographic findings were admitted to the ICU, and the 2 patients who had in-house mortality had all 3 findings on bedside echocardiography. Despite the smaller numbers in this study, a reasonable preliminary conclusion is that the diagnosis of pulmonary embolism, with signs of advanced right ventricular dysfunction on bedside echocardiography (right ventricular dilatation with right ventricular hypokinesis, McConnell's sign, or paradoxical septal motion), tends to occur in patients with a larger clot burden who are more likely to be admitted to an ICU setting. These observations are hypothesis generating because our study was not powered to examine these additional advanced echocardiographic findings. Additional research is required to further examine these advanced findings and to incorporate them into clinical treatment plans.

Furthermore, our study found that, in general, the incidence of right ventricular dilatation and advanced signs of right ventricular dysfunction are higher in patients with more proximal emboli, which would logically contribute a higher clot burden. As seen in Table 3, all 4 patients with saddle emboli and most patients with lobar and mainstem emboli had signs of right ventricular dilatation on the bedside echocardiography. In contrast, the majority of patients with segmental emboli as their most proximal site had a normal bedside echocardiographic result. In addition, all ICU

patients (Table 4) had larger clot burdens with signs of right ventricular dilatation, and most had evidence of advanced right ventricular dysfunction on echocardiography. Because of the small number of patients in this study, larger multicenter trials would need to be conducted to evaluate the statistical association between clot burden and the presence or absence of right ventricular dilatation and dysfunction.

Early initiation of anticoagulation has been associated with improved mortality for patients with pulmonary embolism.²⁹ Unfortunately, there are many reasons for delay in obtaining diagnostic imaging, such as the need to establish intravenous access, confirm normal renal function before obtaining a CT scan, and wait for CT availability. At one academic institution, the median time to definitive diagnosis of a pulmonary embolism (defined as the time of patient arrival to the ED to the time the pulmonary embolism was diagnosed on CT) was 2.4 hours, with 25% of patients waiting longer than 7.6 hours until diagnosis.²⁹ Although there is no clear acceptable wait time for initiating anticoagulation in a patient with a pulmonary embolism, the consensus is that earlier treatment is preferred. The American College of Chest Physicians' clinical practice guidelines advocate anticoagulation before definitive testing for patients with a high clinical suspicion of acute pulmonary embolism and for patients with moderate clinical suspicion of acute pulmonary embolism and an anticipated delay in diagnostic testing of more than 4 hours.²⁸ In addition, a recently published decision analysis found that for patients with a Wells score greater than 4 and an anticipated delay to diagnosis of 1.7 hours, anticoagulation before diagnosis is favored.³⁰

Despite published clinical guidelines encouraging empiric anticoagulation, only 9% of patients with confirmed pulmonary embolism receive anticoagulation before definitive diagnosis.³¹ The decision to empirically start anticoagulation is complicated by the risks of treatment. The risk of major bleeding from anticoagulation depends on clinical characteristics such as age and associated malignancy. Recent studies estimate 30-day bleeding rates to be 2.03% for low-risk patients and 3.44% for high-risk patients, with half of these bleeding events occurring within the first 2 weeks of treatment.^{32,33} Nearly 25% of these bleeding events are fatal.³³ It is likely that many physicians are hesitant to start anticoagulation therapy before definitive diagnosis. In addition, despite that there is evidence showing the presence of right ventricular dilatation on echocardiography in certain patients who never develop hemodynamic instability, but still have a worse prognosis (recurrent pulmonary embolism, chronic right ventricular dilatation, and right ventricular failure), the use of thrombolytics or other more aggressive therapies in this subset of patients warrants further studies.^{5,34,35}

A larger sample size or multicenter trials would be needed to confirm the diagnostic performance of the finding of right ventricular dilatation on bedside echocardiography. Although the positive likelihood ratio in our study is very high, a larger sample size would narrow the CI and provide a more precise estimate. Likewise, trials designed to measure the change in time to diagnosis, safety, and

efficacy of early anticoagulation based on bedside echocardiography results are needed. Pulmonary embolism is a highly lethal, time-sensitive entity and its treatment has significant risks. Our study indicates that a point-of-care ultrasound test could be a valuable addition to the diagnostic protocol for patients with suspected pulmonary embolism. For a patient with moderate to high clinical suspicion of pulmonary embolism and a bedside echocardiographic result demonstrating right ventricular dilatation, earlier anticoagulation could be initiated. If our findings were confirmed, then a clinical trial examining the initiation of anticoagulation based on point-of-care ultrasound findings of right ventricular dilatation would be an appropriate next step.

The authors would like to thank James Feldman, MD, MPH, for his help with edits and review of this article.

Supervising editor: Allan B. Wolfson, MD

Author affiliations: From the Northwestern University Feinberg School of Medicine, Department of Emergency Medicine, Chicago, IL (Dresden); the New York University School of Medicine, Department of Emergency Medicine, New York, NY (Carmody); the Boston University School of Medicine, Department of Emergency Medicine, Boston, MA (Mitchell, Rahimi, Leo, Rubin-Smith, Langlois, Bibi); the Department of Biostatistics, Boston University School of Public Health, Boston, MA (White); and the University of Vermont College of Medicine, Division of Emergency Medicine, Department of Surgery, Burlington, VT (Sullivan).

Author contributions: PM and KC conceived the study, designed the trial, and supervised the conduct of the trial and data collection. SD, ML, AS, and KC collected the data, including performing the echocardiography. LR and JR-S undertook recruitment of patients and managed the data, including quality control. SB, BL, and LW provided statistical advice on study design and analyzed the data. SD and KC drafted the article, and all authors contributed substantially to its revision. KC takes responsibility for the paper as a whole.

Funding and support: By *Annals* policy, all authors are required to disclose any and all commercial, financial, and other relationships in any way related to the subject of this article as per ICMJE conflict of interest guidelines (see www.icmje.org). The authors have stated that no such relationships exist.

Publication dates: Received for publication January 26, 2013. Revision received July 14, 2013. Accepted for publication August 21, 2013. Available online September 27, 2013.

Presented as a poster at the American College of Emergency Physicians *Scientific Assembly*, October 2011, San Francisco, CA.

Address for correspondence: Kristin Carmody, MD, RDMS, E-mail kristin.carmody@nyumc.org.

REFERENCES

1. Pineda LA, Hathwar VS, Grant BJB. Clinical suspicion of fatal pulmonary embolism. *Chest*. 2001;120:791-795.
2. Stein PD, Henry JW. Prevalence of acute pulmonary embolism among patients in a general hospital and at autopsy. *Chest*. 1995;108:978-981.

3. Morgenthaler TI, Ryu JH. Clinical characteristics of fatal pulmonary embolism in a referral hospital. *Mayo Clin Proc.* 1995;70:417-424.
4. Tapson PF. Acute pulmonary embolism. *N Engl J Med.* 2008;358:1037-1052.
5. Goldhaber SZ. Pulmonary embolism. *Lancet.* 2004;363:1295-1305.
6. Carson JL, Kelley MA, Duff A, et al. The clinical course of pulmonary embolism. *N Engl J Med.* 1992;326:1240-1245.
7. Heit JA, Silverstein MD, Mohr DN, et al. Predictors of survival after deep vein thrombosis and pulmonary embolism: a population-based, cohort study. *Arch Intern Med.* 1999;159:445-453.
8. Goldhaber SZ, Visani L, De Rosa M. Acute pulmonary embolism: clinical outcomes in the International Cooperative Pulmonary Embolism Registry (ICOPER). *Lancet.* 1999;353:1386-1389.
9. Horlander KT, Mannino DM, Leeper KV. Pulmonary embolism mortality in the United States, 1979-1998: an analysis using multiple-cause mortality data. *Arch Intern Med.* 2003;163:1711-1717.
10. Grifoni S, Olivetto I, Cecchini P, et al. Short-term clinical outcome of patients with acute pulmonary embolism, normal blood pressure, and echocardiographic right ventricular dysfunction. *Circulation.* 2000;101:2817-2822.
11. Kasper W, Konstantinides S, Geibel A, et al. Prognostic significance of right ventricular afterload stress detected by echocardiography in patients with clinically suspected pulmonary embolism. *Heart.* 1997;77:346-349.
12. Kucher N, Rossi E, DeRosa M, et al. Prognostic role of echocardiography among patients with acute pulmonary embolism and a systolic arterial pressure of 90 mm Hg or higher. *Arch Intern Med.* 2005;165:1777-1781.
13. Jardin F, Dubourg O, Gueret P, et al. Quantitative two-dimensional echocardiography in massive pulmonary embolism: emphasis on ventricular interdependence and leftward septal displacement. *J Am Coll Cardiol.* 1987;10:1201-1206.
14. Okubo S, Miyatake K, Nagata S, et al. Role of echocardiography in acute pulmonary embolism. *Jpn Heart J.* 1989;30:655-664.
15. McConnell MV, Solomon SD, Rayan ME, et al. Regional right ventricular dysfunction detected by echocardiography in acute pulmonary embolism. *Am J Cardiol.* 1996;78:469-473.
16. Come PC. Echocardiographic evaluation of pulmonary embolism and its response to therapeutic interventions. *Chest.* 1992;101(4 suppl):151S-162S.
17. Wood KE. Major pulmonary embolism: review of a pathophysiologic approach to the golden hour of hemodynamically significant pulmonary embolism. *Chest.* 2002;121:877-905.
18. Nijkeuter M, Sohne M, Tick L, et al. The natural course of hemodynamically stable pulmonary embolism: clinical outcome and risk factors in a large prospective cohort study. *Chest.* 2007;131:517-523.
19. Jelinek GA, Ingarfield SL, Mountain D, et al. Emergency department diagnosis of pulmonary embolism is associated with significantly reduced mortality: a linked data population study. *Emerg Med Australas.* 2009;21:269-276.
20. Labovitz AJ, Noble VE, Bierig M, et al. Focused cardiac ultrasound in the emergent setting: a consensus statement of the American Society of Echocardiography and American College of Emergency Physicians. *J Am Soc Echocardiogr.* 2010;23:1225-1230.
21. Wolde MT, Sohne M, Quak E, et al. Prognostic value of echocardiographically assessed right ventricular dysfunction in patients with pulmonary embolism. *Arch Intern Med.* 2004;164:1685-1689.
22. Sanchez O, Trinquart L, Colombet I, et al. Prognostic value of right ventricular dysfunction in patients with haemodynamically stable pulmonary embolism: a systematic review. *Eur Heart J.* 2008;29:1569-1577.
23. American College of Emergency Physicians. ACEP emergency ultrasound guidelines. *Ann Emerg Med.* 2009;53:550-570.
24. Bova C, Greco F, Misuraca G, et al. Diagnostic utility of echocardiography in patients with suspected pulmonary embolism. *Am J Emerg Med.* 2003;21:180-183.
25. Kasper W, Meinertz T, Henkel B, et al. Echocardiographic findings in patients with proved pulmonary embolism. *Am Heart J.* 1986;112:1284-1290.
26. Kasper W, Geibel A, Tiede N, et al. Distinguishing between acute and subacute massive pulmonary embolism by conventional and Doppler echocardiography. *Br Heart J.* 1993;70:352-356.
27. Miniati M, Monti S, Pratali L, et al. Diagnosis of pulmonary embolism: results of a prospective study in unselected patients. *Am J Med.* 2001;110:528-535.
28. Guyatt GH, Akl EA, Crowther M, et al. Executive summary: *Antithrombotic Therapy and Prevention of Thrombosis*, 9th ed: American College of Chest Physicians Evidence-Based Clinical Practice Guidelines. *Chest.* 2012;141(2 suppl):7S-47S.
29. Smith SB, Geske JB, Maguire JM, et al. Early anticoagulation is associated with reduced mortality for acute pulmonary embolism. *Chest.* 2010;137:1382-1390.
30. Blondon M, Righini M, Aujesky D, et al. Usefulness of preemptive anticoagulation in patients with suspected pulmonary embolism: a decision analysis. *Chest.* 2012;142:697-703.
31. Pollack CV, Schreiber D, Goldhaber SZ, et al. Clinical characteristics, management, and outcomes of patients diagnosed with acute pulmonary embolism in the emergency department: initial report of EMPEROR (Multicenter Emergency Medicine Pulmonary Embolism in the Real World Registry). *J Am Coll Cardiol.* 2011;57:700-706.
32. Ruiz-Gimenez N, Suarez C, Gonzalez R, et al. Predictive variables for major bleeding events in patients presenting with documented acute venous thromboembolism. Findings from the RIETE Registry. *Thromb Haemost.* 2008;100:26-31.
33. Nieto JA, Solano R, Ruiz-Ribo MD, et al. Fatal bleeding in patients receiving anticoagulant therapy for venous thromboembolism: findings from the RIETE registry. *J Thromb Haemost.* 2010;8:1216-1222.
34. Kreit JW. The impact of right ventricular dysfunction on the prognosis and therapy on normotensive patients with pulmonary embolism. *Chest.* 2004;125:1539-1545.
35. ACEP Clinical Policies Committee and the Clinical Policies Subcommittee on Suspected Pulmonary Embolism. Clinical policy: critical issues in the evaluation and management of adult patients presenting with suspected pulmonary embolism. *Ann Emerg Med.* 2003;41:257-270.