# VT versus SVT with aberrancy
# EKG Criteria

**Features favoring VT**

**AV dissociation**

Fusion/Dressler (capture) beats

2:1 ventriculoatrial block

Slightly irregular R-R intervals

**Absence of RS complex in the precordial leads**

QRS concordance in the precordial leads similar to normally conducted beats

Initial vector of abnormal QRS complex

Predominantly negative QRS complexes in $V_4$ - $V_6$

QR complexes present in $V_2$ - $V_6$

**R-S width > 100ms in at least one precordial lead**

QRS duration > 140ms

Extreme left superior axis deviation

Net area under QRS negative in leads I and II

**Features favoring SVT w/aberrancy**

Consistent onset of tachycardia with PACs

Short RP interval (<0.1 sec)

1:1 ventriculoatrial relationship

Regular R-R intervals

Triphasic pattern in $V_1$

**Table 1. Important distinguishing characteristics of mechanisms of wide-complex tachycardias**

| Characteristic | Ventricular tachycardia | Rate-related aberrancy | Preexcitation tachycardia |
|---|---|---|---|
| AV dissociation (more QRS than P waves) | Rules in | Practically rules out | Practically rules out |
| Captured beats | Rules in | Rules out | Rules out |
| Fusion beats | Rules in | Rules out | Rules out |
| Rhythm (ventricular) | Regular, except torsade de pointes | Regular, except AF and MAT | Regular, except AF and MAT |
| QRS axis | Leftward shift supports diagnosis | Usually normal | Usually normal |
| QRS duration > 140 msec | Strongly supports diagnosis | Almost never occurs | Rare |
| Remote myocardial infarction | Common | Usually not present | Usually not present |
| Normal heart | Uncommon | Common | Common |
| Response to carotid massage | None | May terminate if AV node–dependent | May terminate if AV node–dependent |
| Response to Valsalva maneuver | None | May terminate if AV node–dependent | May terminate if AV node–dependent |

AF, atrial fibrillation; AV, atrioventricular; MAT, multifocal atrial tachycardia.

***MORPHOLOGY CRITERIA***

**Features favoring VT**

RBBB pattern:

- Monophasic R or biphasic qR, QR, or RS in $V_1$
- S > R or QS in $V_6$

**Features favoring SVT w/aberrancy**

RBBB pattern:

- Triphasic rSR' in $V_1$
- Triphasic rSR' in $V_6$

LBBB pattern:

- Broad R wave or wide R-S length (> 30msec) in $V_1$ or $V_2$
- Notched downstroke of S-wave in $V_1$ or $V_2$
- > 60msec to nadir of S in $V_1$ or $V_2$
- qR or QS pattern in $V_6$

- R > S in $V_6$

LBBB pattern:

- No R in $V_1$
- Small narrow R in $V_2$
- No slurring of S-wave downstroke
- Monophasic R in $V_6$
- Presence of septal Q in I & $V_6$

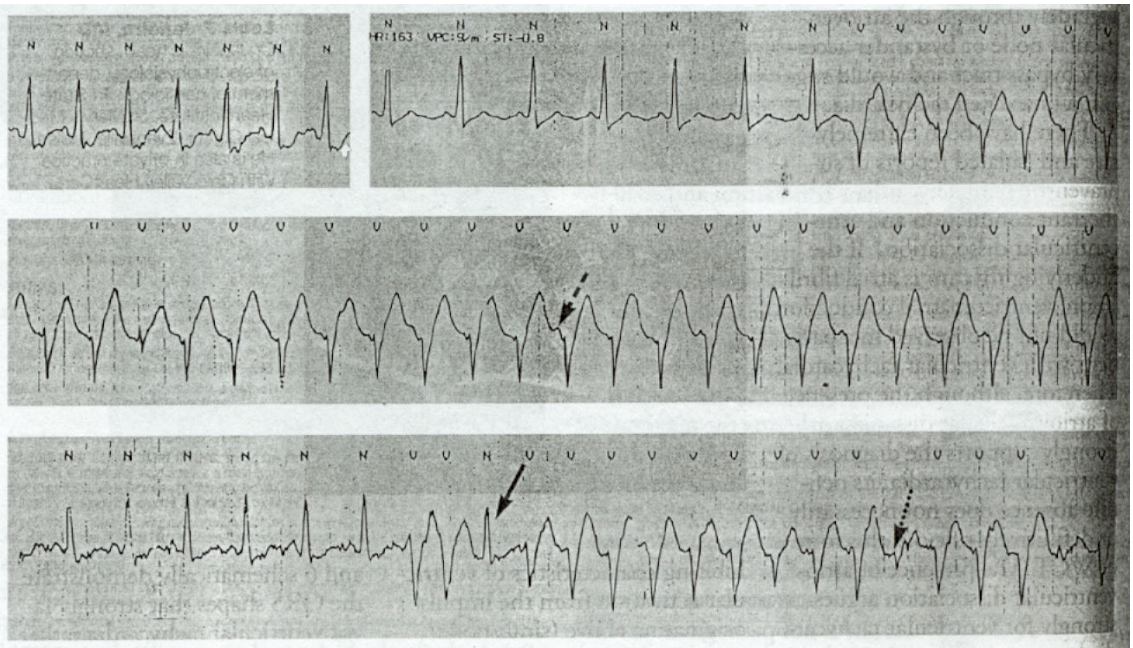

**Figure 4.** Lead II monitor rhythm strip of patient with remote myocardial infarction who presented with recurrent near-syncope. Frequent nonsustained as well as sustained wide-complex tachycardias (WCTs) were documented at 160 bpm. Recognizable features are atrioventricular dissociation (broken arrow), captured beats (solid arrow), and fusion beats (dotted arrow). These observations strongly favor ventricular tachycardia. Patient was subsequently shown in the electrophysiology laboratory to have easily inducible ventricular tachycardia, which matched the spontaneous morphologic characteristics of WCT.

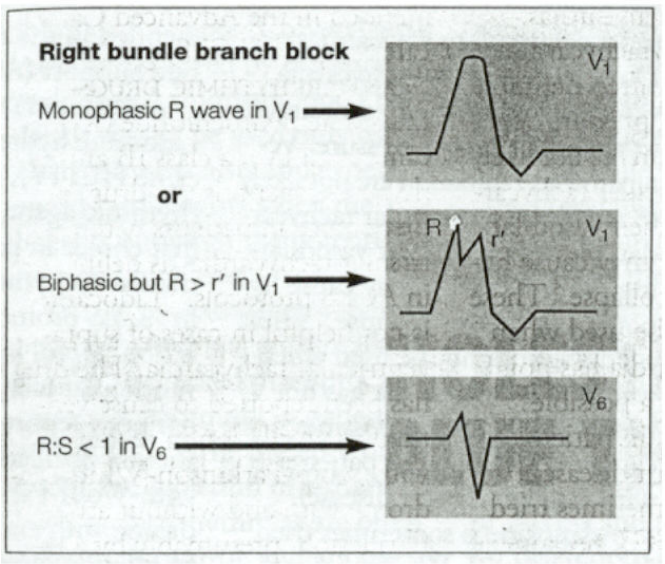


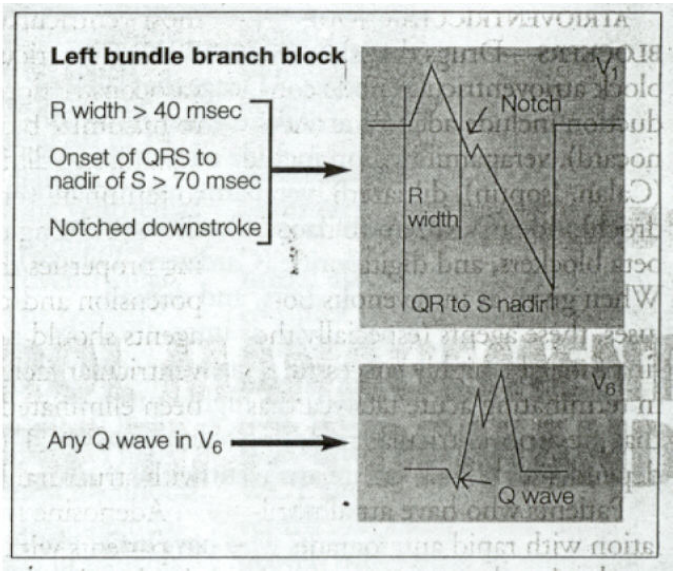

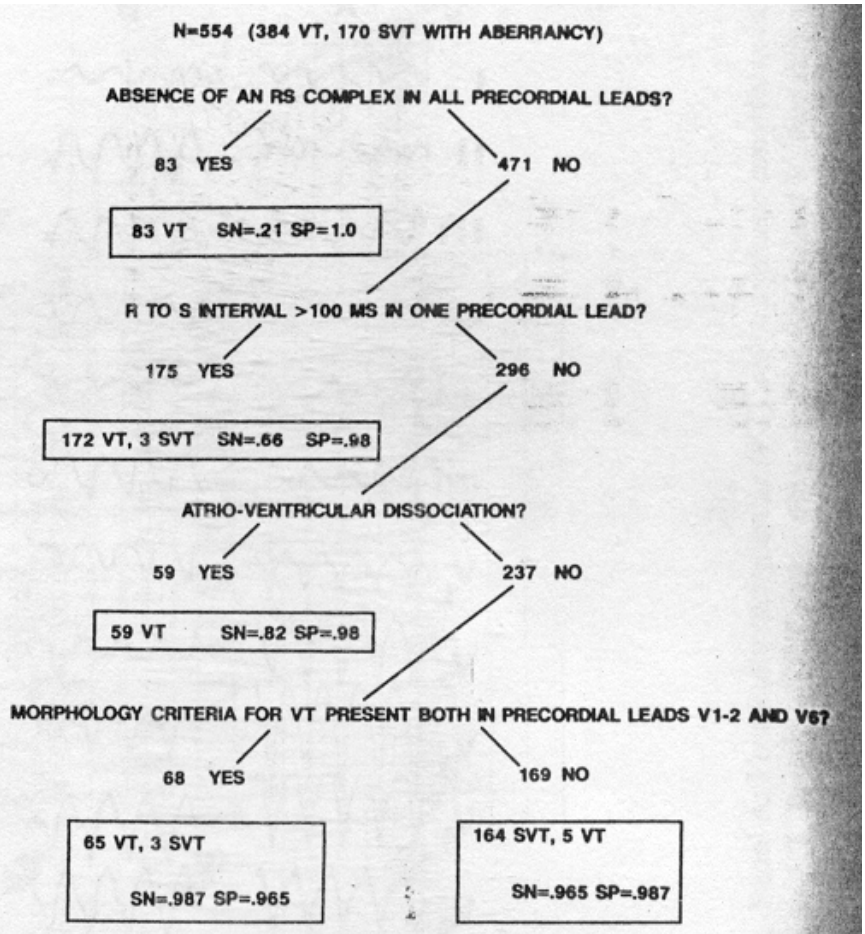


FIGURE 7. *Algorithm of the diagnosis made by two observers in 554 tachycardias with a widened QRS complex. Number of tachycardias classified at each step is given. Sensitivities (SN) and specificities (SP) for the diagnosis of ventricular tachycardia (VT) are also shown at each step and also for the diagnosis of supraventricular tachycardia (SVT) with aberrant conduction at the last step. Note that the four consecutive criteria reached a sensitivity of 0.987 and a specificity of 0.965 for the diagnosis of VT and of 0.965 and 0.987 for the diagnosis of SVT with aberrant conduction.*

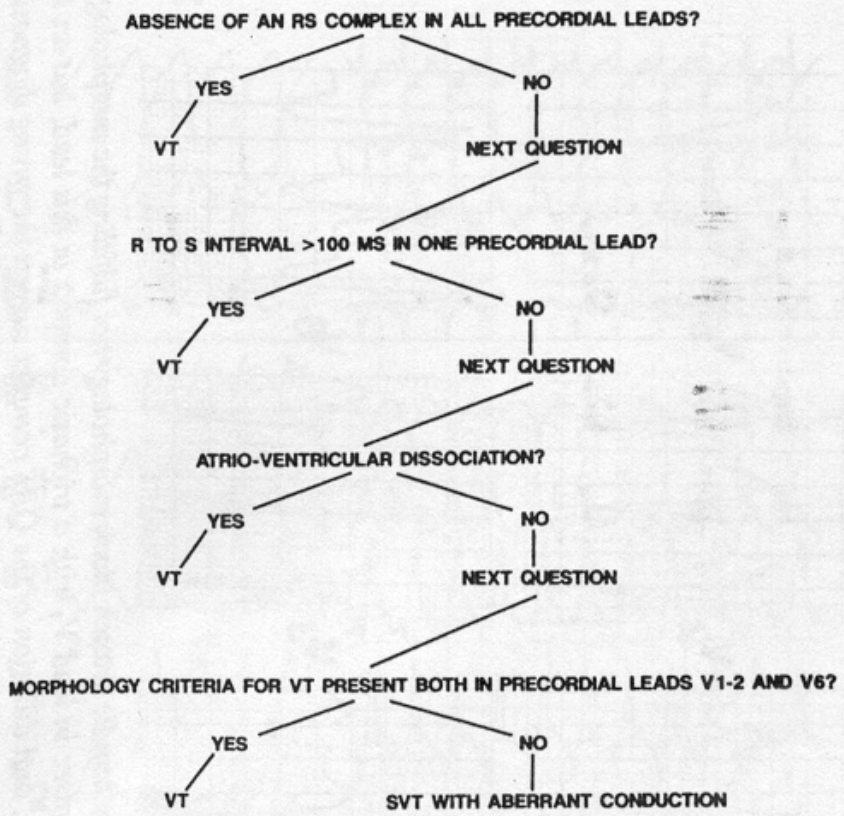


FIGURE 1. *Algorithm for diagnosis of a tachycardia with a widened QRS complex. When an RS complex cannot be identified in any precordial lead, the diagnosis of ventricular tachycardia (VT) is made. If an RS complex is present in one or more precordial leads, the longest RS interval is measured. If the RS interval is longer than 100 msec, the diagnosis of VT is made. If shorter than 100 msec, the next step of the algorithm is considered: whether atrioventricular dissociation is present. If present, the diagnosis of VT is made. If absent, the morphology criteria for VT are analyzed in leads $V_1$ and $V_6$. If both leads fulfill the criteria for VT, the diagnosis of VT is made. If not, the diagnosis of supraventricular tachycardia (SVT) with aberrant conduction is made by exclusion of VT.*

References

Wellens, et al. The value of the electrocardiogram in the differential diagnosis of a tachycardia with a widened QRS complex.
*Am J Med* 1977; 64: 27-33.
Brugada, et al. A new approach to the differential diagnosis of a regular tachycardia with a wide QRS complex.
*Circulation* 1991; 83: 1649-59.

D. Suh 12/13/00