



Focus On

Extensor tendon injury

Introduction

Extensor tendon injury has the potential to seriously impair hand function. In recent years, there has been considerable work directed towards defining the best repair and rehabilitation techniques in order to maximise functional return. This short review focuses specifically on extensor tendon injury to the fingers. Consideration will be given to the surgical anatomy, biomechanics, implant design, surgical tips, reported outcomes and complications for arthroplasty of the metacarpophalangeal joint (MCPJ), proximal interphalangeal joint (PIPJ) and first carpometacarpal joint (CMCJ). Readers are directed to the implant manufacturers' literature for information on implantation technique.

Clinical Anatomy

The anatomy of the extensor tendons is well described in the literature and only key points of functional relevance will be included here.¹⁻³ In the fingers, the extensor system is a complex arrangement of intrinsic and extrinsic musculotendinous units with associated ligaments, receiving innervation from the radial, median and ulnar nerves. The thumb is somewhat simpler, benefiting from a dedicated extrinsic extensor for both phalanges and a long abductor for the metacarpal, all of which are innervated by the radial nerve.

In the finger, the extrinsic tendons have three major insertions – the sagittal bands, the bases of the middle and distal phalanges, and a minor attachment at the base of the proximal phalanx. Through these insertions, the extrinsic tendons act as the principal extensors at the metacarpophalangeal joint (MCPJ), but only have a secondary function of interphalangeal joint (IPJ) extension. Primary IPJ extension is through the action of the intrinsic system, and the addition from the extrinsic system is through the insertion at the proximal phalanx.

Separated by the deep intermetacarpal ligament, the lumbricals and interossei both act volar to the axis of rotation of the MCPJs and, therefore, the intrinsic system may paradoxically flex these joints. By virtue of this complex arrangement, the extensor mechanism acts with the flexor tendons to give the fingers a precise positioning potential over the entire joint range. Despite the comparatively small excursion necessary for their action, there is a precise balance of forces and positional arrangements between individual components of the extensor system. The extensor mechanism is, therefore, highly sensitive to violation through disturbance of length or anatomical position following injury or during operative repair.

In clinical practice, extensor tendon injuries are usually classified into one (or more) of the nine (I-IX) individual zones originally described by Verdan.⁴ The zone of injury is important as it may guide towards appropriate treatment and prognosis.

Initial assessment and injury patterns

Patients with a possible extensor tendon injury require thorough documentation of the mechanism of injury, examination of the hand and supporting radiographs to obtain an accurate assessment of all injured structures. Open injuries should be expediently irrigated with normal saline, and tetanus prophylaxis provided with appropriate antibiotics.

With regards to closed injuries, the extensor mechanism can characteristically fail under situations of extreme load, either at the insertion of the central slip (zone III) or the terminal tendon (zone I). These injuries can produce characteristic pictures known respectively as boutonnière or mallet deformities. However, a boutonnière, and to a lesser extent a mallet deformity may not appear acutely and can take several weeks to show.

Injuries to the central slip can, therefore, be challenging to identify. The risk of missing the diagnosis and the possible, subsequent development of a boutonnière deformity, often merits a presumptive diagnosis and period of empirical splintage. Likewise, an untreated mallet injury may be complicated by not only an extensor lag at the distal IPJ (DIPJ), but also the development of a 'swan-neck' deformity as excess tension builds at the central slip insertion into the base of the middle phalanx. Secondary correction of swan-neck or boutonnière deformities can be very challenging and, therefore, prevention by early splintage is essential for a satisfactory outcome.

Injuries in zones II and IV are frequently created by lacerations and often only damage part of the tendon. This is because the curvature of the tendons over the dorsum of the phalanges offers some degree of protection from complete laceration. Therefore, many authors advocate the conservative management of simple tendon lacerations in these zones if the degree of tendon involvement is less than 50% and the patient still has full extension across the injury zone.^{1,2} Injuries at zone V may frequently follow a human bite and often require initial control of infection before tendon repair can be attempted. Closed or blunt trauma at zone V can damage the sagittal bands leading to ulnar subluxation of the extensor tendon, which may be identified through an inability to actively extend the flexed MCPJ, but maintenance of extension when the finger has been passively

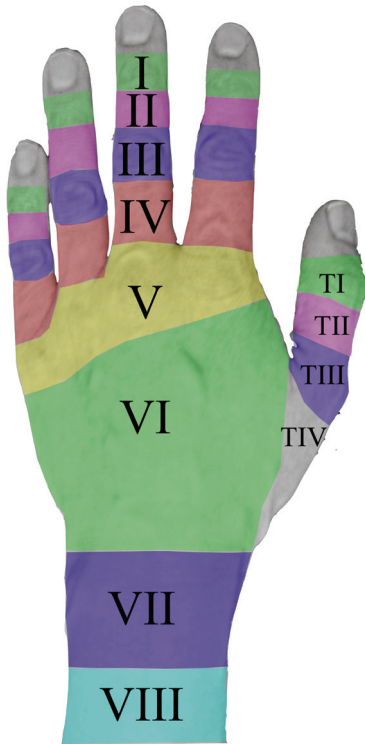

Fig. 1

Zones of Extensor Tendon Injury

straightened. Injuries proximal to zone V may be masked by either the presence of juncturae tendinum (intertendinous connections), or extension via extensor digiti minimi (EDM) or extensor indicis proprius (EIP). These injuries require careful examination for diagnosis, but have a better chance of a good outcome following repair compared with injuries in zones I to IV.⁵

Techniques of operative repair

Despite the comparative ease of surgical access, extensor tendon repair is technically demanding in all zones of injury. General considerations include meticulous surgical technique and tissue handling to avoid further iatrogenic damage to the fragile tendon edges. This mandates the use of good quality instruments. Open injuries require wound excision and debridement of non-viable tissue combined with thorough lavage. Associated injuries must be addressed as these may impact on tendon adhesion during healing, especially in zones I to IV.

Surgical considerations specific to extensor tendons include their reduced size compared with the flexors and their lack of collagen-bundle cross linkage, which reduces the grip strength available to suture material.⁶ In addition, the cross-section of the extensors changes from semicircular to a biconcave disk in zones I to IV, thereby making a durable repair more challenging because of the thin but broad profile of the tendon.⁷ Furthermore, the flat tendon profile in zones I to IV increases the surface area between the repaired tendon and its adjacent tissues, especially bone, and predisposes to increased adhesion formation.

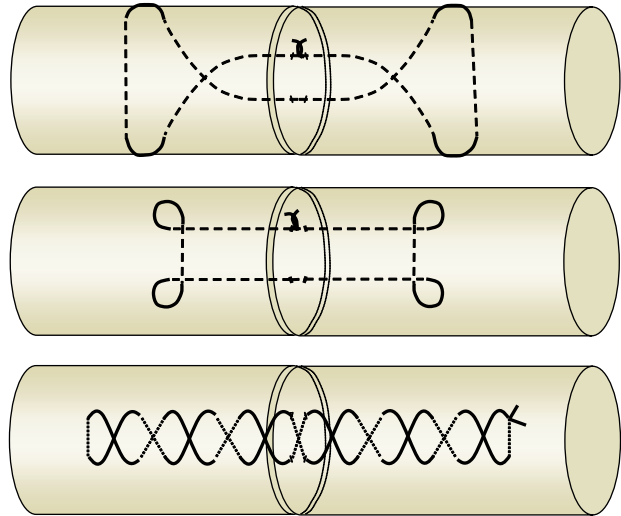


Fig. 2

Three well-established suture techniques for use in extensor tendon repair: a) modified Bunnell, b) modified Kessler, c) modified Becker.

Many studies have been undertaken to establish the best suture techniques in the different zones and how to rehabilitate the repair for the best long-term outcome.^{6,8-10} Although gapping at the repair site can produce an extensor lag, the most frequent and severe consequence seen after extensor tendon repair is loss of flexion. This may be either through adhesion formation or excessive shortening at the repair site. Tendon shortening is particularly apparent proximal to zone V; four commonly used suture techniques, including the modified Kessler, modified Bunnell, mattress and figure-of-eight, all shorten the tendon by a mean of 6 mm during repair in this region.⁶ The same suture techniques produce less shortening distal to zone V, suggesting that the poorer results in this region may largely be created by adhesion formation.⁹

Suture techniques that cross the direction of collagen fibres have consistently demonstrated the greatest strength under load and resistance to gap formation. These include the modified Bunnell, modified Kessler and augmented Becker techniques. Each may be used distally in the finger as well as more proximally in zones VI to VIII (Fig. 2). More recently, interest has focussed on an interlocking mattress suture that compares favourably in terms of strength with the modified Bunnell or augmented Becker types, but without the shortening associated with these techniques when used in zone VI.¹⁰ Suture material can be non-absorbable nylon, polypropylene, or absorbable materials such as polydioxanone.

Rehabilitation

The ultimate goal of treatment of an extensor tendon injury is to obtain healing with minimal gapping and, more importantly, avoidance of adhesions. A team approach between surgeon and hand therapist is essential in order to select the best therapeutic regime for an individual patient. This may need to be tailored to the specific individual, with adjustments made as rehabilitation progresses.⁵

For closed or open mallet injuries at zone I, and zone II injuries, the DIPJ is maintained in extension for six weeks followed by controlled active-motion exercises and night-time extension splintage for a further four to six weeks.³

For more proximal injuries, traditional approaches to post-operative rehabilitation involved static splintage for a period of at least six weeks before mobilisation exercises were begun. This approach is still advocated by some for use in poorly compliant patients and in situations where there is associated bony injury.¹¹ There has, however, been a move away from static splintage towards controlled active mobilisation. This may be commenced immediately post-operatively for injuries between zones III and VIII.^{5,12} The rationale for this is based upon the premise that tendon glide reduces adhesion to the surrounding tissues. Also, mobilisation is associated with enhanced DNA synthesis at the repair site, increased vascularity and, most significantly, improved tensile strength.^{2,13,14}

In an analysis of several studies that contrasted static immobilisation versus early controlled movement for uncomplicated injuries in zones V to VIII, only 54 to 95% good or excellent results were obtained with the former treatment compared with at least 90% good or excellent results for the latter.^{5,15} Furthermore, despite the accepted poorer outcomes for injuries in zones III and IV, overall results are similarly improved through regimes employing early active short arc motion (SAM) rather than static splintage.¹⁶

The early mobilisation regime involves either dynamic splintage, using a splint-mounted outrigger device to permit tendon glide while protecting against undue load, or the more simplified early controlled active mobilisation methods, such as the Norwich regime.¹⁷ The Norwich approach again uses protective splintage, while providing wrist extension and allowing MCPJ movement between full extension and flexion of at least 50°.

While both techniques offer excellent outcomes, dynamic splintage is comparatively expensive, unwieldy and requires large amounts of therapist time and input. For these reasons, many authors support early active mobilisation over dynamic mobilisation as their rehabilitation method of choice in zones proximal to zone III.^{18,19}

Chris Milner, MB ChB, BSc, MRCS, PhD, Clinical Fellow

Peter Russell MSc, FRCS(Plast), Consultant Hand and Plastic Surgeon
Pulvertaft Hand Centre, Royal Derby Hospital, Derby DE22 3NE.

References

1. **Rockwell WB, Butler PN, Byrne BA.** Extensor tendon: anatomy, injury, and reconstruction. *Plast Reconstr Surg* 2000;106:1592-603.
2. **Newport ML.** Extensor Tendon Injuries in the Hand. *J Am Acad Orthop Surg* 1997;5:59-66.
3. **Matzon JL, Bozentka DJ.** Extensor tendon injuries. *J Hand Surg* 2010;35A:854-61.
4. **Verdan, C. E.** Primary and Secondary Repair of Flexor and Extensor Tendon Injuries. In: J. E. Flynn (Ed.), *Hand Surgery*, Second ed. Baltimore: Williams & Wilkins, 1975.
5. **Newport ML, Tucker RL.** New perspectives on extensor tendon repair and implications for rehabilitation. *J Hand Ther* 2005;18:175-81.
6. **Newport ML, Williams CD.** Biomechanical characteristics of extensor tendon suture techniques. *J Hand Surg* 1992;17A:1117-23.
7. **Woo SH, Tsai TM, Kleinert HE, Chew WY, Voor MJ.** A biomechanical comparison of four extensor tendon repair techniques in zone IV. *Plast Reconstr Surg* 2005;115:1674-81.
8. **Greenwald DP, Hong HZ, May JW Jr.** Mechanical analysis of tendon suture techniques. *J Hand Surg* 1994;19A:641-7.
9. **Newport ML, Pollack GR, Williams CD.** Biomechanical characteristics of suture techniques in extensor zone IV. *J Hand Surg* 1995;20A:650-6.
10. **Lee SK, Dubey A, Kim BH, Zingman A, Landa J, Paksima N.** A biomechanical study of extensor tendon repair methods: introduction to the running-interlocking horizontal mattress extensor tendon repair technique. *J Hand Surg* 2010;35A:19-23.
11. **Russell RC, Jones M, Grobbelaar A.** Extensor tendon repair: mobilise or splint? *Chir Main* 2003;22:19-23.
12. **Howell JW, Merritt WH, Robinson SJ.** Immediate controlled active motion following zone 4-7 extensor tendon repair. *J Hand Ther* 2005;18:182-90.
13. **Hitchcock TF, Light TR, Bunch WH, Knight GW, Sartori MJ, Patwardhan AG, Hollyfield RL.** The effect of immediate constrained digital motion on the strength of flexor tendon repairs in chickens. *J Hand Surg* 1987;12A:590-5.
14. **Feehan LM, Beauchene JG.** Early tensile properties of healing chicken flexor tendons: early controlled passive motion versus postoperative immobilization. *J Hand Surg* 1990;15A:63-8.
15. **Newport ML, Blair WF, Steyers CM Jr.** Long-term results of extensor tendon repair. *J Hand Surg* 1990;15A:961-6.
16. **Evans RB.** Early active short arc motion for the repaired central slip. *J Hand Surg* 1994;19A:991-7.
17. **Sylaidis P, Youatt M, Logan A.** Early active mobilization for extensor tendon injuries. The Norwich regime. *J Hand Surg* 1997;22B:594-6.
18. **Bulstrode NW, Burr N, Pratt AL, Grobbelaar AO.** Extensor tendon rehabilitation a prospective trial comparing three rehabilitation regimes. *J Hand Surg* 2005;30B:175-9.
19. **Khandwala AR, Webb J, Harris SB, Foster AJ, Elliot D.** A comparison of dynamic extension splinting and controlled active mobilization of complete divisions of extensor tendons in zones 5 and 6. *J Hand Surg* 2000;25B:140-6.